

Management of Permanent Facial Fillers Complications Using Radiological Assessment as a Guide for Surgical Removal

ABDELMOHSEN K. ABOUELDAHAB, M.D. and AMR GALAL, M.D.*

The Departments of Plastic & Reconstructive Surgery and Radiodiagnosis, Faculty of Medicine, Alexandria University*

ABSTRACT

Soft tissue fillers for soft tissue augmentation and the correction of wrinkles have been used widely in recent years. As the use of fillers increases, many complications have arisen recently. The range of complications varies widely, local and temporary reactions to the filler is common and self-limited.

These complications have to be treated immediately and properly. Polyacrylamide gel (PAG) is a synthetic and durable filler, which is used in dermatology and plastic surgery to augment skin defects of the face and breasts. When complications such as foreign body reaction to PAG, induration, migration, or infection develop, the filler should be removed; however, it is a difficult procedure and despite multiple attempts to extract, some residues would remain. Milking and aspiration through a needle were previously used to remove PAG in the face.

Aim of the Work: We aimed to refine the outcome of the removal of complicated or displaced permanent facial fillers (PAG) after accurate radiological assessment.

Patients and Methods: The study was carried out on seventy female patients presented to the plastic surgery clinic at Shaab Medical Center in Kuwait in the period from October 2012 till January 2015.

Results: Patients reported no serious complication except three with residual bulk and another two patients suffered from zygomatic nerve weakness for almost two months and recovered completely.

Conclusion: Satisfying removal of permanent facial filler (PAG) can be achieved based on the clinical presentation confirmed by the accurate radiological localization using either US, CT or MRI images. Complete removal is not possible and surgical excision still plays important role in the management of complicated permanent facial fillers.

Key Words: *Soft tissue fillers – Complications – Nodularity – Migration – Suction evacuation.*

INTRODUCTION

Soft tissue fillers for soft tissue augmentation and the correction of wrinkles have been used widely in recent years. Various kinds of products

have been developing and the demand for these products is growing more and more rapidly. The popularity of soft tissue fillers was based on the safety profile, easy application and low complications rate [1]. As the use of fillers increases, many complications have arisen recently. The range of complications varies widely, local and temporary reactions to the filler are common and self-limited. Ozturk et al. [1] named the minimal and self-limited complications simply as adverse sequelae. Misplacement of filler, allergic reaction, infection and biofilm formation, and delayed granulomatous reaction can occur and proper treatments are necessary [1-3]. Skin necrosis and visual impairment are not common but it is a disaster to both the patient and the clinician [4,5]. These complications have to be treated immediately and properly. Polyacrylamide gel (PAG) is a synthetic and durable filler, which is used in dermatology and plastic surgery to augment soft tissue defects of the face and breasts. This translucent material is composed of 2.5% 5% cross-linked polyacrylamide and sterile water. In contrast to other biocompatible fillers, i.e. collagen, hyaluronic acid, and calcium hydroxyapatite, PAG provides permanent effects as it cannot be degraded by enzymes and hence, it is not bioresorbable [6,7]. Although finding a material with permanent effects was a great advance in the preceding decades, these materials have their own downsides. While the manufacturer states that PAG is not displaced easily or cause allergic reactions, fibrosis, or capsules [8], the literature shows that these complications are quite frequent [7,9-11]. When complications such as foreign body reaction to PAG, indurations, migration, or infection develop, the filler should be removed; however, it is a difficult procedure and despite multiple attempts to extract, some residues would remain. Milking and aspiration through a needle were previously used to remove PAG in the face [12].

Plastic surgeons and dermatologists are familiar with the nature and property of most commonly used fillers and their injection technique. Good experience is necessary to prevent various complications because injection technique is critical. Although clinicians take care of above-mentioned factors, complications can develop unexpectedly. Clinicians should be aware of the method to deal with the complications. In this article, we review how to manage the complications of permanent facial fillers after accurate radiological localization.

Aim of the work:

We aimed to refine the outcome of the removal of complicated or displaced permanent facial fillers (PAG) after accurate radiological assessment. The exact site and character of PAG was determined radiologically and the sites were marked on the face before surgical removal of materials.

PATIENTS AND METHODS

The study was carried out on seventy female patients presented to the plastic surgery clinic at Shaab Medical Center in Kuwait in the period from October 2012 till January 2015. All patients who have had facial augmentation using the permanent polyacrylamide gel (PAG) and presented with complications were included in the study. Patients with fat transfer or fillers other than polyacrylamide or patients with unrealistic expectations of complete filler removal and patients with coagulopathies were excluded.

The reasons for filler removal were either being unhappy patients with the results or developing complications of injection such as indurations, migration, cyst formation, over filling, repeated infection, psychological fear of developing future complications and unsightly sagging cheeks.

Cautious history of the previous injected fillers in other clinics was mandatory to be aware of the quality and quantity of the filler we plan to remove. Data concerning basic characteristics, region of injection, complications and radiological data were documented. All patients signed a written informed consent before initiating the diagnostic and therapeutic procedures.

Radiological study:

Because of different patients referral sources, some patients were referred with their radiological study either ultrasonography, CT, or MRI images. Therefore, the patients were selected randomly and this study was not meant to be a comparative study between the different radiological imaging modalities or to recommend the best radiological

mean to describe the facial filler sites and complications. Still the advantages and disadvantages of each radiological modality were shown during the practice. Reviewing the patient's files revealed that ultrasound was used mainly to confirm the clinical diagnosis of fillers related infection or abscess formation and to roughly assess the amount and location of the injected filler.

Computed tomography (CT) or magnetic resonance image (MRI) were recently used as diagnostic tools. Based on the data collected from the imaging reports we could explain the possibility of removing the filler after correlating with the clinical findings. Cystic consistency indicates fast and smooth removal with short down time regards oedema, fibrosis and indurations. Firm to solid masses denote somewhat difficult removal with the possibility of facial nerve trauma and residual fibrosis.

The radiologist determined the size, depth and extension of PAG foci and location of fibrosis in his report. The face was marked according to the photographs findings. This improves the accuracy of the surgeon's performance during evacuation.

Surgical procedure:

Antibiotic was started three days prior to the procedure. Patients were anesthetized either locally with sedation or generally according to their wish and tolerability.

No tumescent fluids were infiltrated in the patients of this study. The filler was injected in malar region, zygomatic region, mid cheek, nasolabial fold, marionette line, and periorbital region.

A preauricular stab with blade number 11 was done; a liposuction blunt spatulated cannula number 3 was used so as not to injure the facial nerve branches. We used a metal snapper (Byron Body Aesthetics by Mentor) to maintain constant pressure once the cannula is within the cyst. In case of not available snapper it was replaced by a strong towel clip holding the pistol of the syringe to maintain vacuum effect. By slow and slight pressure, the cannula was guided to the cyst and penetrated through its wall. A 50-mL syringe was used to vacuum the material within the cysts or nodules. The suction was performed until no more materials could be evacuated and the aspirate became mainly bloody. Often only one entry site is needed, and the cannula can be directed to remove product in multiple passes. This is particularly effective for nodules in the periorbital or perioral areas. The resultant material structure looks like toothpaste it may have a clear granular look tinged with pink color, or be intermixed as small fragmented clumps

within frank blood. If the resultant was purulent a soft rubber drain was inserted for 3-4 days. It is important to stress to patients that this technique will not remove all of the filler.

This process was repeated for all areas that had been localized by the radiologist. A bimanual cheek examination is essential to assess any residual filler left behind. After finishing filler suction, irrigation was done with clear saline mixed with ceftriaxone 1 gm.

Follow-up and assessment of the results:

Patients were followed-up weekly for the first month and then monthly for six months. A standard visual analogue scale (VAS) was used to subjectively evaluate the patient satisfaction, with zero and ten indicating the least and the most satisfied status, respectively.

RESULTS

Seventy female patients with complicated permanent facial filler, their age ranges between 29-55 years were operated upon for filler removal. Preoperative radiologic filler localization was done using US in 35 patients (50%), MRI in 20 patients (28.6%) and CT in 15 patients (21.4%). Five patients (7.1%) were referred because of abscess formation, 5 patients (7.1%) for migration, and 15 (21.4%) for indurations and nodularity of filler and 20 patients (28, 6%) because of recurrent infection (Tables 1,2).

All patients required single session for filler removal except three (3.4%) needed another session for evacuation of a residual bulk. 68 patients (97.4%) reported no infection attacks during the one year follow-up period and they were free to have cosmetic procedure cautiously. Two patients (2.6%) had recurrent attacks of infection following early trial to correct facial asymmetry after two months of filler removal.

Patients reported no serious complication except three with residual bulk (3.4%) and another two patients (2.6%) suffered from zygomatic nerve weakness for almost two months and recovered completely. Another two patients, (2.6%) suffered sagging of the

cheeks after secondary correction with fat transfer as they had intact cyst wall and dead space which accommodate further injection. These patients required minor face lift procedure to obliterate the dead space.

Bruising and edema subsided between 2-4 weeks and cosmetic invasive procedures were allowed after a period of six months.

Regarding assessment of subjective patient's satisfaction on VAS, 58 patients (83.7%) had reported full satisfaction (VAS score, 8-10). Ten patients (had reported moderate satisfaction (experienced irregular cheek contours and sought correction which was done six months later using fat graft) (14.2%) and only two patients (2.65%) were almost unsatisfied with the results (VAS score of 5) (Table 3).

Forms of presentation and causes for removal

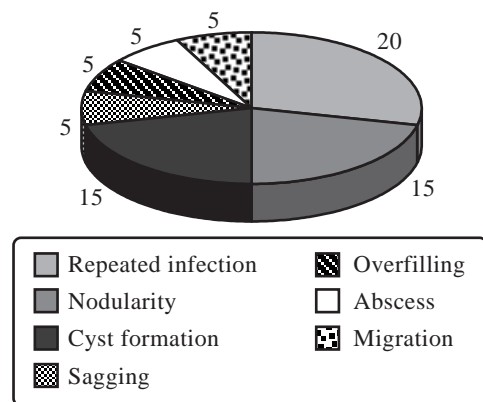


Table (1): Forms of presentation and causes for removal.

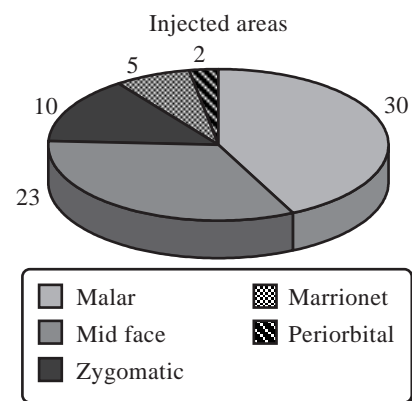
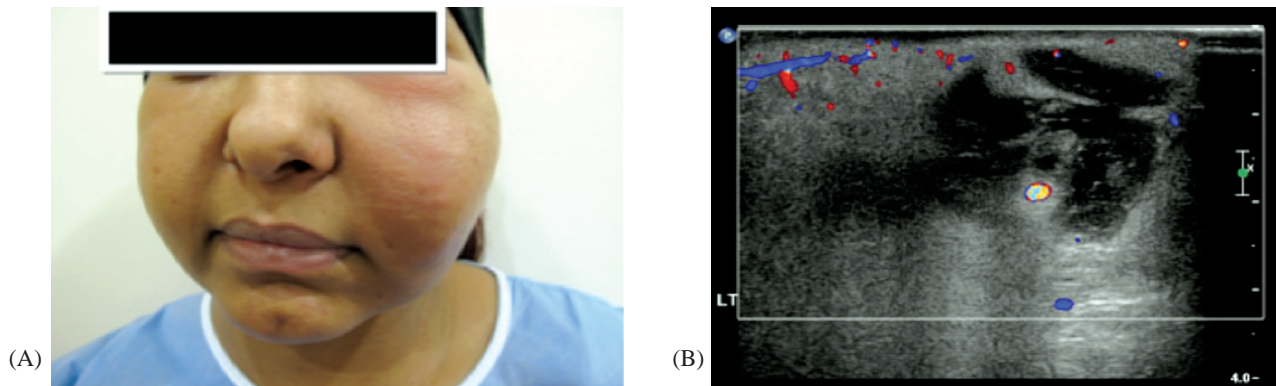


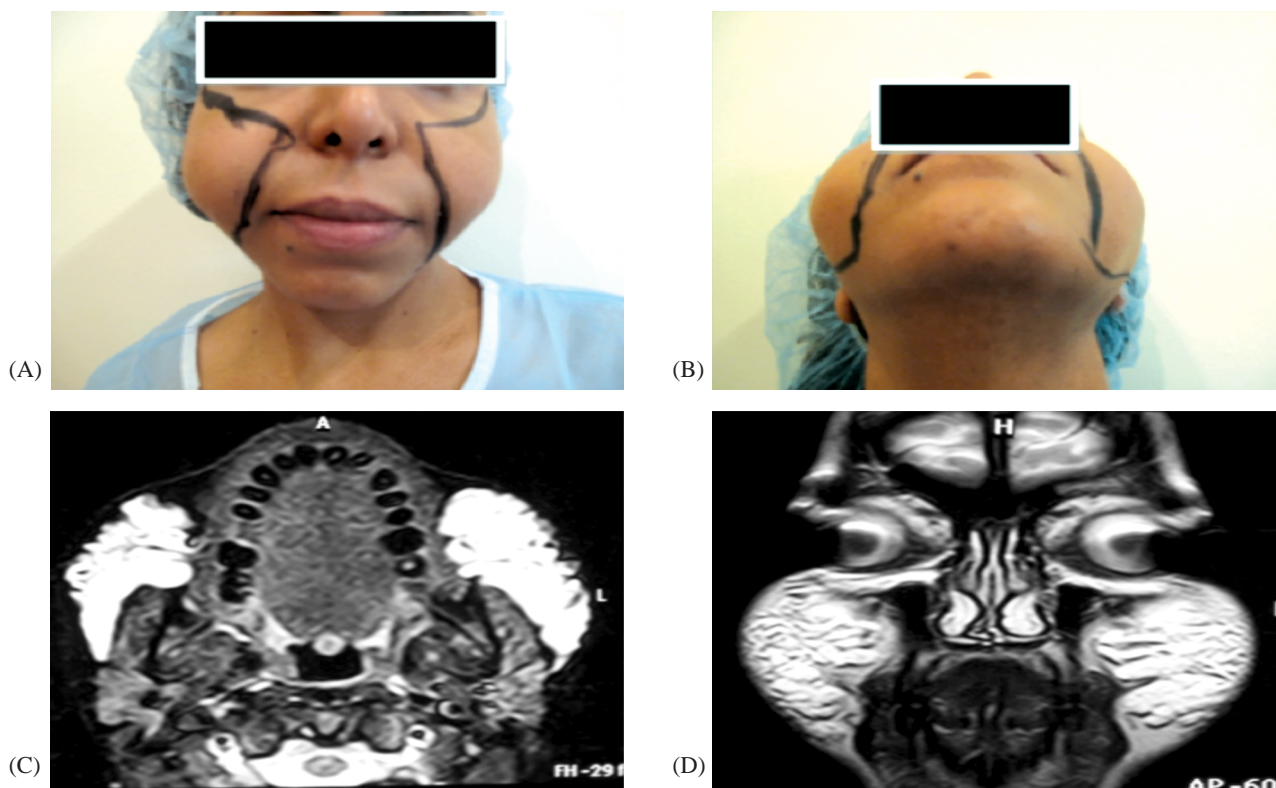
Table (2): Injected areas of the face.

Table (3): Postoperative patient's data.

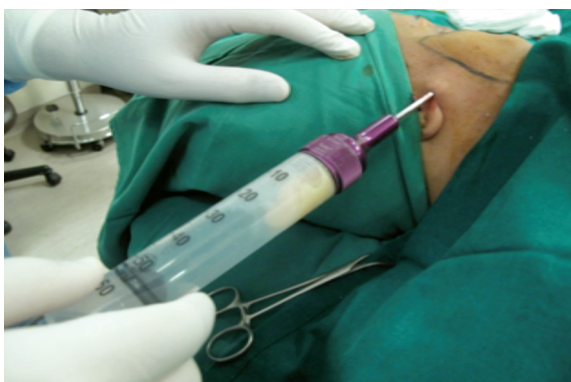Number of sessions	Recurrent infection	Residual bulk	Nerve transient trauma	VAS (visual analogue scale) assessment of patient satisfaction
Single: 67 (95.7%)	None: 68 (97.4%)	Three (4.4%)	Two (2.8%)	58 (83.7%) full satisfaction with score 8-10
Two: 3 (4.3%)	1 attack: 2 (2.6%)			10 score 6-8 (14.2%)
More: 0	More :0			2 (2.65%) score <5



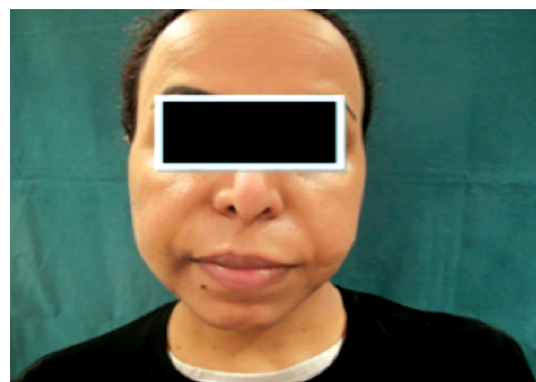Case (1): (A) View of a 49-year-old lady presented with left cheek abscess 4 years after injections of polyacrylamide gel for malar augmentation. (B) Ultrasound image showing a large superficial multiloculated facial abscess at the left cheek.



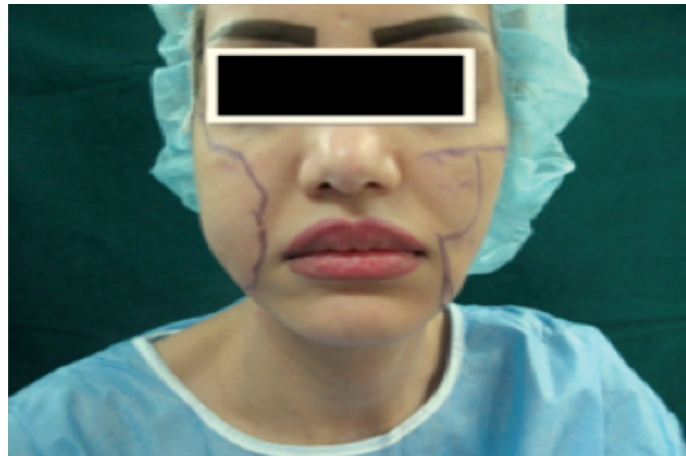Case (2:A-D): Overfilling and sagging cheeks (A,B) 36 year-old-female with large deposits of permanent filler in the cheeks 6 years ago with asymmetric distribution, resulted in contour deformity notably on the right side. (C) Axial and (D) Coronal T2 fat saturated MRI revealed overcorrection with excess filler agent injection exhibiting high T2 signal intensity giving asymmetrical distribution and lumpiness of the injected fillers.



Case (2-E): Intraoperative filler suction.

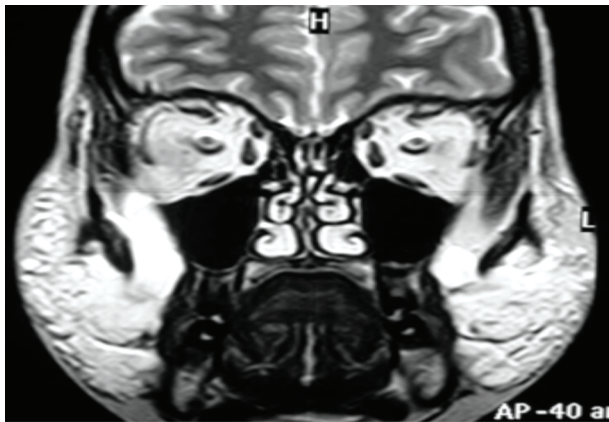


Case (2-F): Postoperative one month.

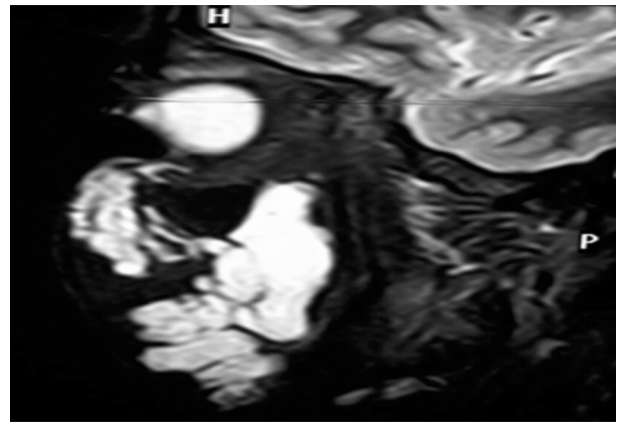


(A)

Case (3): Migration. (A) 35 year-old-female patient presented with cheek nodularity more on the right side 6 years after permanent filler injection in the cheeks.

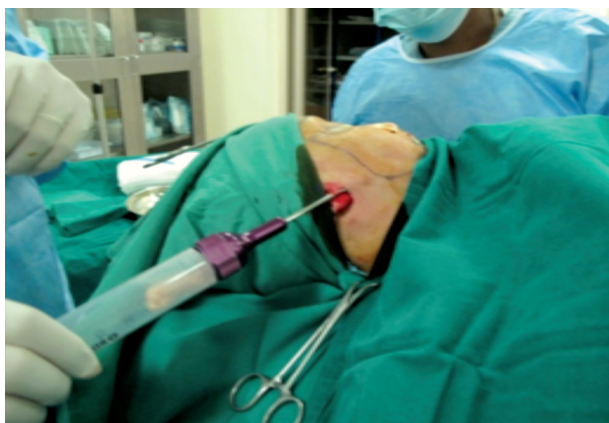

(B)

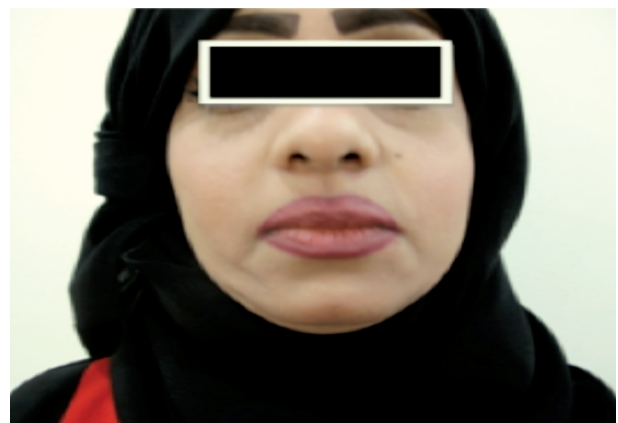

(C)

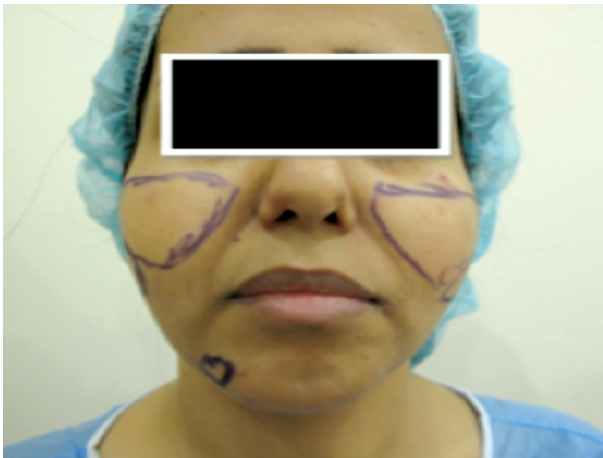Case (3): (B) Coronal and (C) Sagittal fat-suppressed T2 MR images show migration of the injected filler into the deep buccal regions, extending superiorly deep to the temporalis muscle into the infra-orbital region on the right side.



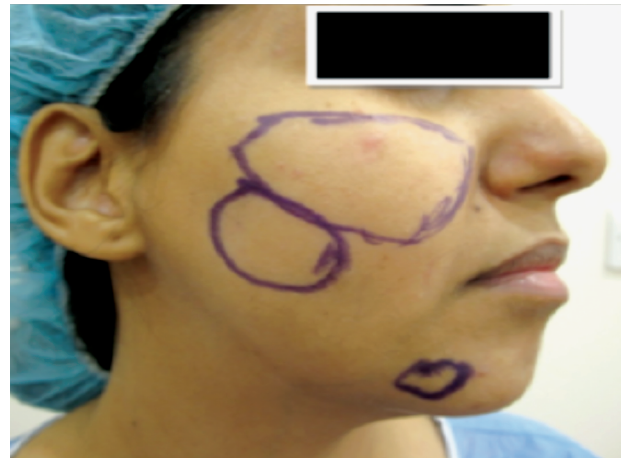Case (3-D): Intraoperative view.



Case (3-E): Three months postoperative view.

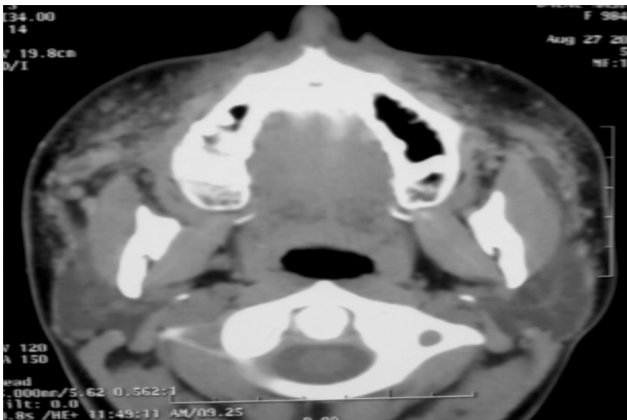


(A)

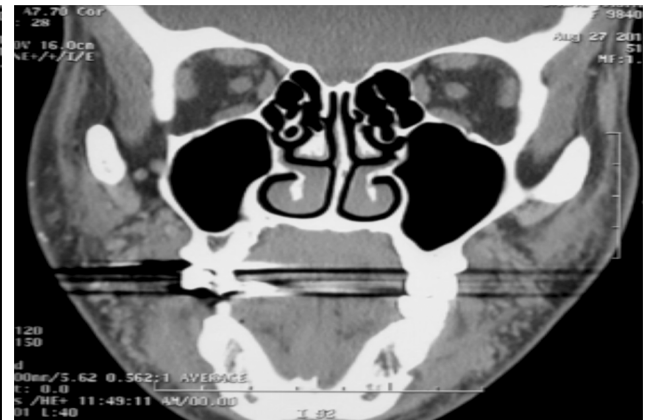

(B)

Case (4): (A,B) Preoperative views of a 32 years lady with cheek cystic nodularity following permanent facial filler for cheek augmentation 7 years ago.

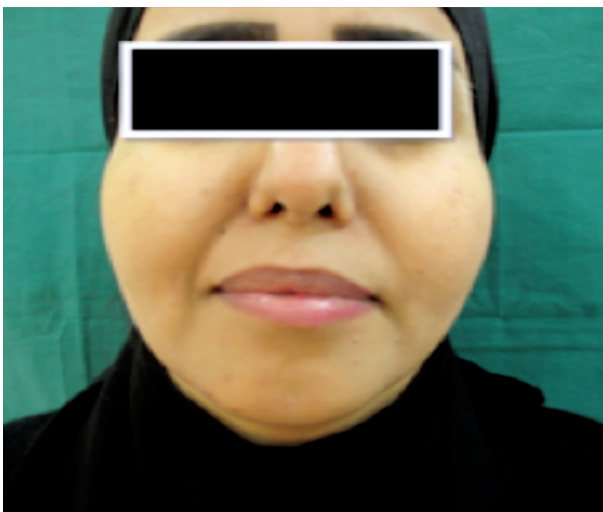

(C)



(D)

Case (4): (C) Axial and (D) Coronal reconstructed CT images show bilateral irregular nodular soft tissue attenuation with stranding of the subcutaneous tissue of the cheeks after 7 years of injection of permanent facial fillers (arrows) denoting chronic subcutaneous inflammatory response.



Case (4-E): Postoperative view after three months.

DISCUSSION

Filler injection is a relatively simple means of facial augmentation and is one of the most commonly performed cosmetic procedures. A wide variety of filler materials are currently on the market, which all have their unique qualities, advantages, and disadvantages [13]. The decision as to which filler to use is a complex one, beyond the scope of this discussion.

Injecting cosmetic fillers is increasing worldwide and desiring cheap permanent filler had led to increased use of PAG as filler in cosmetic procedures. Although the results of facial augmentation by using PAG have been promising, case reports and studies with a longer follow-up period have revealed that various complications can occur

[14,15]. Nonetheless, there are numerous reports on the complications of PAG years after injection [7,9,10,12,16].

For instance, Manafi et al., reported 98 patients with dissatisfactory results and complications of PAG injection including inflammation, infection, abscess formation, and gel migration, which were treated with incision, milking, and irrigation [16]. Reda-Lari et al., reported a complication rate of 8.4% among more than 1300 patients after three-month to six-year follow-up [17]. Also, our previous report on filler complications showed increased rate of infection in about 6.6% of our 686 cases with PAG [18].

Most noteworthy and serious of these is delayed infection, the rate and severity of which depend on the quantity of the gel used and the technical quality of the procedure. It has been proposed that late-occurring infection may be related to additional repeated injections as well as a decreased immune response [19]. Alijotas-Reig et al., and others noted that injection with filling agents of different compositions seems to increase the odds of an immunogenic event, and delayed-onset complications may subsequently arise with either the new implant or previous ones [20,21]. Similarly, contamination of the injected material with microbes can cause long-term chronic infections as a result of biofilm formation, which some researchers believe is an important component of delayed-onset nodule formation [22,23].

Surgeons treating permanent facial fillers complications are faced with three main problems, firstly combating repeated attacks of infection, secondly, detecting filler locations and characters accurately, and thirdly, correcting cheeks asymmetry or irregularities following filler removal. For those who were presented with cheek cellulites or abscess, drainage covered with imperical antibiotic was successful in reducing the filler bulk. Yet, they were vulnerable for further attacks of inflammation depending on the residual fillers and the procedure they were subjected to. These patients usually gave the history of developing the infection following injection of mesotherapy, derma roller, skin peeling, dental work and other systemic infections.

Before removal or evacuation of complicated PAG, the exact location and amount of the materials must be determined. Therefore, development of appropriate investigative means to detect injected cosmetic fillers and elucidate the clinical correlates appears to represent an unmet need. The imaging

features of PAG injection into the facial region have been scarcely highlighted in previous literature.

Ginat's review article shows the utility of different imaging modalities, including US, CT and MRI for depicting many of the early and late complications associated with facial fillers [24]. Ultrasonography provides a radiographically sensitive technique to evaluate presence of any collection. In US images, PAG is detected as an oval anechoic pseudocyst with increased echogenicity of the surrounding subcutaneous tissue [25].

To date, Ultrasonography is the first-line imaging modality for dealing with cosmetic fillers. It provides reliable support in the detection, identification, and assessment of the wide range of worldwide commonly used cosmetic fillers [26]. But as it is operator dependant, small foci of fillers can be missed and migrant fillers also can be missed in such cases we resort to Ct or MRI to recognize the distributed filler locations accurately in order to facilitate its removal.

Computed tomography and T-2 weighted magnetic resonance imaging with fat suppression are other alternatives. On CT, PAG deposits appear as nonspecific soft-tissue densities, which may become ill-defined with superimposed inflammation. Eliciting a previous history of facial augmentation is important in the interpretation of the findings. The main role of CT is to estimate the affected area and to identify any drainable abscess in the acute setting. For cases with suspected infection, a contrast-enhanced CT or MR imaging should be performed to detect any rim-enhancing abscesses. For planning of definite surgery, MR imaging is recommended because it is superior in delineating the true volume and distribution of PAG depositions [24].

Although T2-weighted magnetic resonance imaging (MRI) without fat suppression seems to be the best radiologic study to detect the nodules [24], it is not practical due to the cost of MRI and needed time to perform the imaging. Therefore, most of the studies have used US because it is available almost everywhere, is quick, has low cost, and lacks adverse effects of irradiation to the head and neck [27].

In the present study US image was used in 35 patients (50%), MRI in 20 patients (28.4%) and CT in the remaining 15 patients (21.6%). Based on clinical diagnosis of the type of facial filler complications and correlating the radiological report findings with the clinical examination and

Careful history taking was essential in the proper management of such patients. Therefore, in this study, US was used mainly to confirm cheek abscess in five cases (7.1%), and overfilling in fifteen cases (21.3%) which is matching with the report of Wilson et al., who employed US report to evacuate PAG through suction by a 14G, 1.5-inch needle connected to a 10-mL syringe [12]. Also, Kavoussi and Ebrahimi used US images and evacuated delayed PAG indurations in 20 patients through making a hole on the skin by 16 G needle and squeezing the nodule [28].

Ginat used US marking to facilitate the evacuation of PAG, but the nodules were mobile in most of his cases and as they had used small cannula, the cyst escaped the tip of instrument, which would mandate multiple attempts to rupture the fibrous wall of the cyst. In addition, some of the nodules were small and might be missed by the radiologist, hence, they recommend bedside (real-time) US and evacuation under the guide of US [29]. In the current study, there was no difficulty in piercing the cyst wall with the spatulated liposuction cannula not guided by ultrasound but depending on the accurate radiologic localization and cyst contents and the data offered by CT or MRI reports.

Previous reported techniques for filler removal ranged from direct excision, large needle drainage, incision, and drainage via manual expression to copious saline irrigation [7,9,30]. These ordinary means of filler evacuation resulted in continuity of the repeated infections, filler re-accumulation, creation of many tracts and patients dissatisfaction after all.

Ross et al., stated that because patients may have been treated with multiple injections, there may be numerous tracts underneath the skin's surface connecting pockets of the fillers. Like small tubes between the pockets, it is commonly to see one previously drained area re-accumulate with product from another tract [31]. These cases benefit from MRI or CT images to accurately locate the deeply seated nodules and migrating ones and any connecting tracts between the nodules or cysts. Patients need to be educated that they likely will need multiple treatments for further removal to even out irregularities as a consequence [32].

Similar to the study of Ross et al. [31], in 25 patients (35.5%) of the present study, the radiologic images showed deep filler extension, and multiple tracts formation, hence, suction evacuation using the liposuction cannula was preferred over needle aspiration as it penetrated the cysts barriers and

converted them to one single cavity easily to evacuate and curetted the cyst wall, also helped to evacuate all the missing tracts that caused recurrent infection.

Girolamo et al., stated that MRI consistently and clearly demonstrated the precise filler size, site localization and visualizing anatomical landmarks on axial and coronal scans. MRI also, allowed the measurement of filler, assessing the extent and depth in facial soft tissues, with minimum size detected of 2mm [32]. Comparably, the MRI and CT findings in 35 patients (50%) of the current study were matching with those of Girolamo et al., where deep extension, small migratory nodules and cysts, were detected. Therefore, the surgical approach was switched from just needle puncture, milking and direct squeezing to evacuation using liposuction cannula which led to near total removal of the filler and diminution of the nodules size. In addition, the blunt tip of the cannula minimized facial nerve or vessels injuries.

Most patients stated full satisfaction after the filler removal evidenced by the decrease in the recurrent infection episodes after the evacuation to reach 2.6%. On the contrary, in our previous report of 50 patients for whom we evacuated the PAG using needle aspiration, squeezing and suction techniques, the patients had experienced recurrent attacks of infection in 4% and they all needed multiple sessions for filler removal [33].

Removal of PAG can be so problematic that Goldan et al., devised a novel irrigation system as an alternative method. However, all the patients in his particular study were hospitalized for a number of days with the irrigation system sewn in place. Unfortunately, although this treatment is effective, it is neither cost effective nor convenient for the patients [34].

Therefore, using liposuction cannula with proper radiologic filler localization had successfully helped the near total removal of the filler, decreased number of sessions for removal to a single session and moreover decreased incidence of forthcoming complications and patients were allowed to have cosmetic procedures safely afterward. Yet, this technique is not applicable to cases with firm to hard nodules and complete removal of the filler is impossible and surgical excision is mandatory in some cases.

Conclusion:

The use of permanent fillers for facial augmentation and wrinkles reduction should be banned

because of multiple long term complications. Many strategies exist to reduce the risks of filler complications. Removal of PAG by suction is possible but never complete because of biofilm capsular formation, fibrosis, migration and tract formation. Suction evacuation based on accurate radiological filler localization has decreased the incidence of complications, mainly recurrent infection, and improved patient's satisfaction.

Ultrasonography, CT and MRI provide valuable information for treatment planning. MR imaging is more sensitive to distinguish the deposits from surrounding tissues and is the preferred technique in assessing the volume and distribution of PAG for surgical planning.

REFERENCES

- Ozturk C.N., Li Y., Tung R., et al.: Complications following injection of soft-tissue fillers. *Aesthet. Surg J.*, 33: 862-377, 2013.
- DeLorenzi C.: Complications of injectable fillers, Part I. *Aesthet Surg J* 5 aaps Archives of Aesthetic Plastic Surgery Choi W.Y. et al., Complications of Filler, 33: 561-575, 2013.
- Cohen J.L.: Understanding, avoiding, and managing dermal filler complications. *Dermatol. Surg.*, 34 (Suppl 1): S92-99, 2008.
- Lazzeri D., Agostini T., Figus M., et al.: Blindness following cosmetic injections of the face. *Plast. Reconstr. Surg.*, 129: 995-1012, 2012.
- Kwon S.G., Hong J.W., Roh T.S., et al.: Ischemic oculomotor nerve palsy and skin necrosis caused by vascular embolization after hyaluronic acid filler injection: A case report. *Ann. Plast. Surg.*, 71: 333-334, 2013.
- Breiting V., Aasted A., Jorgensen A., Opitz P. and Rosetzsky A.: A study on patients treated with polyacrylamide hydrogel injection for facial corrections. *Aesthetic. Plast. Surg.*, 28 (1): 45-53, 2004.
- Kalantar-Hormozi A., Mozafari N. and Rasti M.: Adverse effects after use of polyacrylamide gel as a facial soft tissue filler. *Aesthet. Surg. J.*, 28 (2): 139-142, 2008.
- Christensen L.H., Breiting V.B., Aasted A., Jorgensen A. and Kebuladze I.: Long-term effects of polyacrylamide hydrogel on human breast tissue. *Plast. Reconstr. Surg.*, 111 (6): 1883-1890, 2003.
- Lee C.J., Kim S.G., Kim L., Choi M.S. and Lee S.I.: Unfavorable findings following breast augmentation using injected polyacrylamide hydrogel. *Plast. Reconstr. Surg.*, 114 (7): 1967-1968, 2004.
- Evstatiev D.: Late complications after injections of hydrogel in the breast. *Plast. Reconstr. Surg.*, 113 (6): 1878, 2004.
- Shen H., Lv Y., Xu J.H., Hong X.Y., Zeng B.W., Xiao W., et al.: Complications after polyacrylamide hydrogel injection for facial soft-tissue augmentation in China: twenty-four cases and their surgical management. *Plast. Reconstr. Surg.*, 130 (2): 340e-348e, 2012.
- Wilson Y.L. and Ellis D.A.: Large needle suction aspiration of permanent fillers. *Laryngoscope*, 121 (10): 2146-2149, 2011.
- Dayan S.H. and Bassichis B.A.: Facial dermal fillers: Selection of appropriate products and techniques. *Aesthet. Surg. J.*, 28: 335-347, 2008.
- Pallua N. and Wolter T.P.: A 5-year assessment of safety and aesthetic results after facial soft-tissue augmentation with polyacrylamide hydrogel (Aquamid): A prospective multicenter study of 251 patients. *Plast. Reconstr. Surg.*, 125 (6): 1797-1804, 2010.
- Liu H.L. and Cheung W.Y.: Complications of polyacrylamide hydrogel (PAAG) injection in facial augmentation. *J. Plast. Reconstr. Aesthet. Surg.*, 63:e9-e12, 2010.
- Manafi A., Emami A., Pooli A.H., et al.: Unacceptable results with an accepted soft tissue filler: Polyacrylamide hydrogel. *Aesth. Plast. Surg.*, 34: 413-422, 2010.
- Reda-Lari A.: Augmentation of the malar area with polyacrylamide hydrogel: Experience with more than 1300 patients. *Aesthet. Surg. J.*, 28 (2): 131-138, 2008.
- Allam A.A., Abou El Dahab A.K. and Ghaly N.R.: Polyacrylamide hydrogel as a long-lasting and permanent soft tissue filler, 4 years experience. *Tanta Med. Sc. J.*, 3 (4): 77-87, 2008.
- Khedher N.B., David J., Trop I., et al.: Imaging findings of breast augmentation with injected hydrophilic polyacrylamide gel: Patient reports and literature review. *Eur. J. Radiol.*, 78: 104-111, 2011.
- Alijotas-Reig J., Garcia-Gimenez V., Miró-Mur F., Vilardell-Tarrés M.: Delayed immune-mediated adverse effects of polyalkylimide dermal fillers: Clinical findings and long-term follow-up. *Arch. Dermatol.*, 144: 637-642, 2008.
- Zager W., Huang J., McCue P. and Reiter D.: Laser resurfacing of silicone-injected skin: the silicone flash revisited. *Arch. Otolaryngol. Head Neck Surg.*, 127: 418-421, 2001.
- Christensen L., Breiting V., Janssen M., Vuust J. and Hogdall E.: Adverse reactions to injectable soft tissue permanent fillers. *Aesthetic. Plast. Surg.*, 29: 34-48, 2005.
- Christensen L.: Normal and pathologic tissue reactions to soft tissue gel fillers. *Dermatol. Surg.*, 33 (Suppl 2): S168-S175, 2007.
- Ginat D.T. and Schatz C.J.: Imaging features of midface injectable fillers and associated complications. *AJNR Am. J. Neuroradiol.*, 34 (8): 1488-1495, 2013.
- Wortsman X.: Common applications of dermatologic sonography. *J. Ultrasound Med.*, 31 (1): 97-111, 2012.
- Wortsman X., Wortsman J., Orlandi C., Cardenas G., Sazunic I. and Jemec G.B.: Ultrasound detection and identification of cosmetic fillers in the skin. *J. Eur. Acad. Dermatol. Venereol.*, 26 (3): 292-301, 2012.
- Indrizzi E., Moricca L.M., Pellacchia V., Leonardi A., Buonaccorsi S. and Fini G.: Biomaterial implantation in facial esthetic diseases: Ultrasonography monitor follow-up. *J. Craniofac. Surg.*, 19 (4): 1098-1103, 2008.
- Kavoussi H. and Ebrahimi A.: Delayed gel indurations as an adverse effect of polyacrylamide filler and its easy treatment. *Dermatol. Res. Pract.*, 2012: 539153, 2012.

- 29- Ginat D.T. and Schatz C.J.: Imaging of Facial Fillers: Additional Insights. American Jour. Neuroradiol., 33: E140-E141, 2012.
- 30- Wolter T.P. and Pallua N.: Removal of the permanent filler polyacrylamide hydrogel (Aquamid) is possible and easy even after several years. Plast. Reconstr. Surg., 126: 138e-139e, 2010.
- 31- Ross A.H. and Malhotra R.: Long-term orbitofacial complications of polyalkylimide 4% (bio-alcamid). Ophthal. Plast. Reconstr. Surg., 25: 394-397, 2009.
- 32- Girolamo M., Mattei M., Signore A. and Grippaudo R.F.: MRI in the evaluation of facial dermal fillers in normal and complicated cases. J. Eur. Radiol., 2014.
- 33- Allam A.A., Hegazy A.M. and Aboueldahab A.K.: Suction-assisted evacuation of facial long lasting and permanent fillers, evaluation of the technique. Tanta Med. Sc. J., 8 (2): 49-55, 2013.
- 34- Goldan O., Georgiou I., Grabov-Nardini G., et al.: Early and late complications after nonabsorbable hydrogel polymer injection: A series of 14 patients and novel management. Dermatol. Surg., 33 (Suppl 2): S199-S206, 2007.